




# DIRECT SUPERIOR

stryker

AN ILIOTIBIAL BAND AND MUSCLE SPARING APPROACH

## Surgical Technique



# Direct Superior Surgical Technique

## Table of Contents

Indications and Contraindications .....	2
Instrumentation .....	3
Step 1. Pre-operative Planning and Templating .....	6
Step 2. Patient Positioning and Draping .....	6
Step 3. Skin Incision and Superficial Dissection .....	7
Step 4. Deep Surgical Dissection .....	8
Step 5. Tendon Detachment and Capsulotomy .....	9
Step 6. Dislocation and Femur Neck Resection .....	10
Step 7. Exposure of the Acetabulum and Retractor Placement .....	11
Step 8. Preparation of the Acetabulum .....	12
Step 9. Cup Insertion .....	13
Step 10. Femoral Exposure .....	15
Step 11. Capsular Repair .....	17
Step 12. Tendon Repair .....	17

## Scientific Advice

**Anthony K. Hedley, MD**  
Chairman, DBA  
AZ Center for Bone & Joint Disorders  
Hedley Orthopaedic Institute  
Phoenix, AZ

**Douglas J. Roger, MD**  
Director of Joint Replacement Service  
Institute of Clinical Orthopedics and Neuroscience  
Desert Regional Medical Center  
Palm Springs, CA

## Intended Use / Contraindications

- The intended user profile is a licensed orthopaedic surgeon or trained OR support under the supervision of a licensed orthopaedic surgeon.
- The intended use of this instrumentation is for performing a Direct Superior Approach total hip arthroplasty. All medical and surgical indications, contraindications and precautions customarily observed for total hip arthroplasty are applicable.
- The intended patient population includes patients who meet the indications provided in the respective implant IFU (see Product Compatibility).

## Warnings and Precautions

- The instrumentation in this technique should not be used to implant any other manufacturer's components. Any such use will negate the responsibility of Stryker Orthopaedics for the performance of the resulting implant.
- See package insert for warnings, precautions, adverse effects, information for patients and other essential product information.

## Product Compatibility

- Compatible femoral stems include:
  - Accolade II
  - Anato
  - Secur-Fit Advanced
- Compatible acetabular systems include:
  - Trident
  - Tritanium
- For specific indications and device descriptions, please refer to implant specific surgical techniques.

## Cleaning & Sterilization

Before using Direct Superior instrumentation, verify:

- Instruments have been properly disassembled prior to cleaning and sterilization;
- Instruments have been properly assembled post-sterilization;
- Instruments have maintained design integrity; and,
- Proper size configurations are available.

For instructions for cleaning, sterilization, inspection and maintenance of orthopaedic medical devices, refer to LSTPI-B and for OEM medical devices refer to IFU D3.3.1.16.

# DIRECT SUPERIOR

## INSTRUMENTATION

### Retractor Tray

Description*	P/N	Qty
Narrow Right Angle Retractor	509574	1
Wide Right Angle Retractor	509575	1
Blue Handle Curved Retractor	509576	1
Curved Retractor	509578	2
S-Curved Retractor	509579	1
Double Ended Retractor	509580	2
Case Base	T510481	1
Case Lid	T510482	1
Interior Retractor Tray	T510484	1


\*OEM medical devices



### Reamer Handle Tray


Description*	P/N	Qty
Femoral Neck Elevator	509577	1
Angled Reamer Handle	510012	1
Case Base	T510481	1
Case Lid	T510482	1
Internal Reamer Handle Tray	T510483	1

\*OEM medical devices



### Acetabular Tray


Description	P/N	Qty
U-Joint Bolt Driver	1440-2017	1
Straight Cup Bolt Impactor	1440-2019	1
Curved Cup Bolt Impactor	1440-2010	1
Lateral Decubitus Alignment Guide	1440-1370	Optional
Cup Impactor Bolt	1440-2011	2
Case	4845-7-600	1
Internal Cup Impactor Tray	1440-2093	1



Observe that components are not visibly damaged prior to use. Examine instrumentation against the tray layout to ensure all parts are accounted for (prior to and following surgery) and available for use.

### Retractors

- A variety of retractors are supplied in the set.
- These include retractors of different widths and profiles to accommodate various exposure objectives and should be used at the discretion of the operating surgeon.



**509574**  
**Narrow Right Angle**  
**Retractor**



**509575**  
**Wide Right Angle**  
**Retractor**



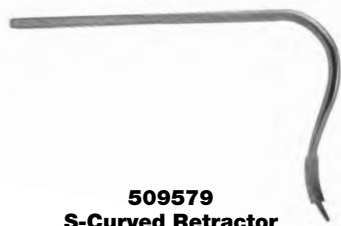**509576**  
**Blue Handle Curved**  
**Retractor**



**509577**  
**Femoral Neck**  
**Elevator**



**509578**  
**Curved Retractor**



**509579**  
**S-Curved Retractor**



**509580**  
**Double Ended**  
**Retractor**

### For Acetabular Preparation



**510012**  
**Angled Reamer Handle**



**1440-2019**  
**Straight Cup Bolt Impactor**



**1440-2010**  
**Curved Cup Bolt Impactor**



**1440-2017**  
**U-Joint Bolt Driver**



**1440-2011**  
**Cup Impactor Bolt**



**1440-1370**  
**Lateral Decubitus Alignment Guide (optional)**

- The Cup Impactors interface with Stryker Trident and Titanium cups via a modular bolt. The bolt provides a method for repeated attachment and detachment of the cup impactor.



# STEP 1

## PRE-OPERATIVE PLANNING AND TEMPLATING

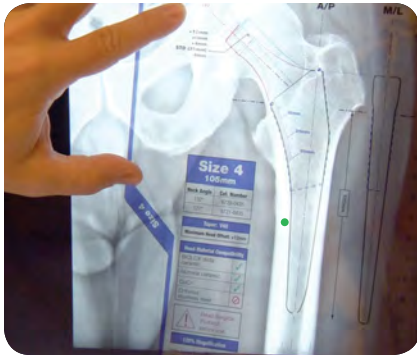


Figure 1

Preoperative planning aids in the selection of the appropriate implant style and size for the patient's hip pathology. It is also used to evaluate:

- Optimal femoral stem fit
- Neck offset
- Acetabular component sizing
- Leg Length
- Assessment of peri-acetabular osteophytes requiring removal

The location of the acetabular component is determined as the initial reference point. From this location, the center of rotation is established.

The femoral template is then applied using the center of rotation as the initial landmark (Figure 1). The size of the femoral component is selected according to the respective surgical technique. Once the femoral component size is selected, the distance from the center of rotation to the respective femoral neck cut is determined. The distance from the lateral shoulder of the femoral prosthesis to the tip of the greater trochanter can be used as a secondary guide, since the lesser trochanter cannot be seen or palpated during the procedure.

# STEP 2

## PATIENT POSITIONING AND DRAPING

The patient is positioned in the lateral decubitus position. The patient is positioned as anterior as possible on the operative table (Figure 2). This is done to facilitate intra-operative adduction of the operative leg. Pelvic positioners are placed anteriorly on the anterior superior iliac spine, and posteriorly on the sacrum. The operative leg is flexed to 90 degrees prior to draping in order to ensure that there is no impingement on the anterior pelvic positioner. It is also adducted to 40 degrees and internally rotated to 40 degrees to ensure that the patient is positioned anteriorly enough on the table, and to confirm that the 40-40-40 position can be achieved intra-operatively (Figure 3).

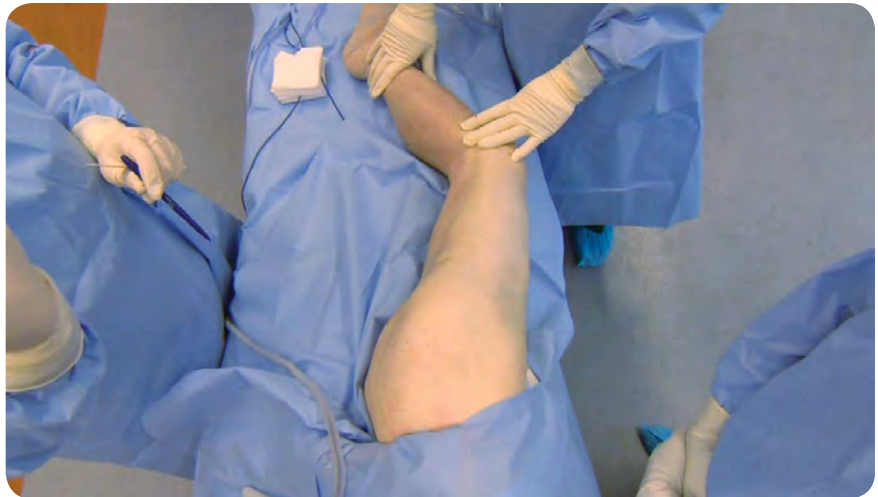

Figure 2



### Note

**The 40-40-40 position refers to 40 degrees of flexion, 40 degrees of adduction, and 40 degrees of internal rotation. This position allows for optimal exposure during femoral preparation.**

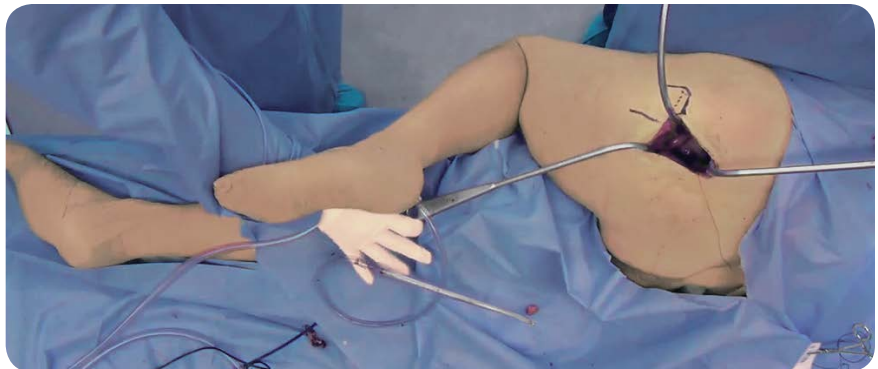


Figure 3

# STEP 3

## SKIN INCISION AND SUPERFICIAL DISSECTION

The anterior, posterior, and superior margins of the greater trochanter are identified and marked on the skin. The initial incision is made a thumbsbreadth distal to the posterosuperior corner of the greater trochanter, corresponding to the attachment of piriformis. The incision extends approximately 9–12 cm, in line with the fibers of the gluteus maximus. (Figure 4).



### Note

**The incision should be straight when hip is flexed to 50-60 degrees.**

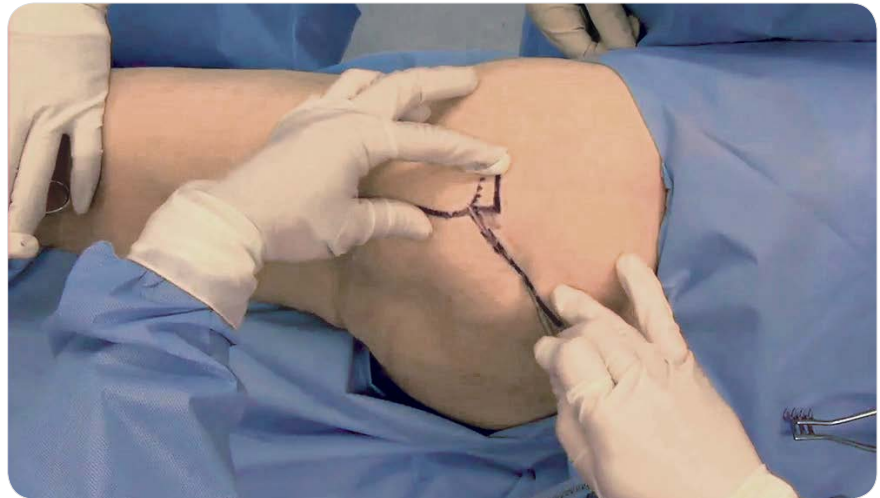

Figure 4

The gluteus maximus fibers are then spread in line with the fascial incision along the longitudinal axis of the muscle fibers. This separation starts at the posterior border of the greater trochanter, and it extends posteriorly for a distance of approximately 8 cm (Figure 5). The deep gluteus maximus fascia is then divided bluntly using a Cobb Elevator, exposing pericapsular fat which is deep to it.

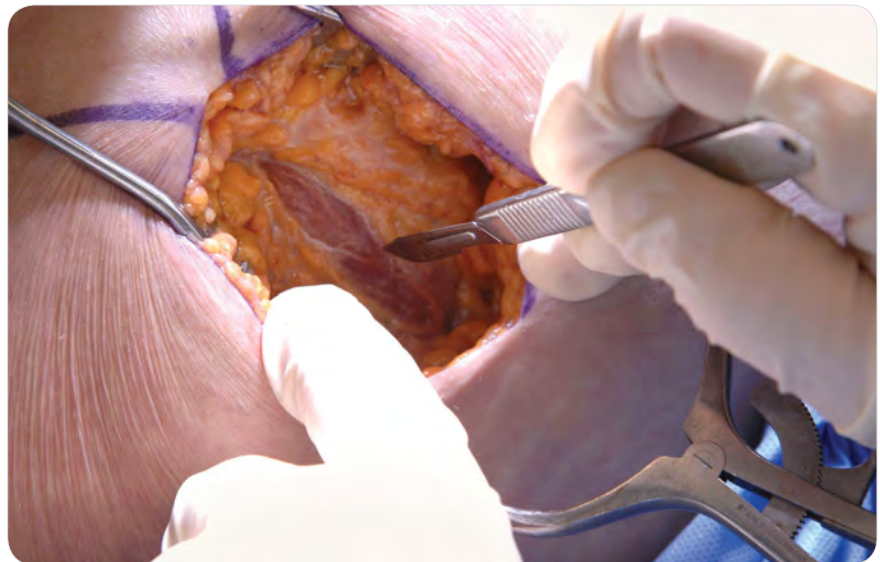


Figure 5



# STEP 4

## DEEP SURGICAL DISSECTION

A Double Ended Retractor (#509580) is placed superior to the tip of the greater trochanter to retract the gluteus medius anteriorly. A second Double Ended Retractor (#509580) is placed along the posterior border of the proximal femur, retracting the soft tissue inferiorly (Figure 6). The pericapsular fat that is just posterior to the greater trochanter is removed using electrocautery. Care is taken not to stray too posteriorly during this portion of the procedure in order to avoid injury to the sciatic nerve. It is not necessary to surgically expose the sciatic nerve. The sciatic notch is superior and posterior to the field of surgical dissection.

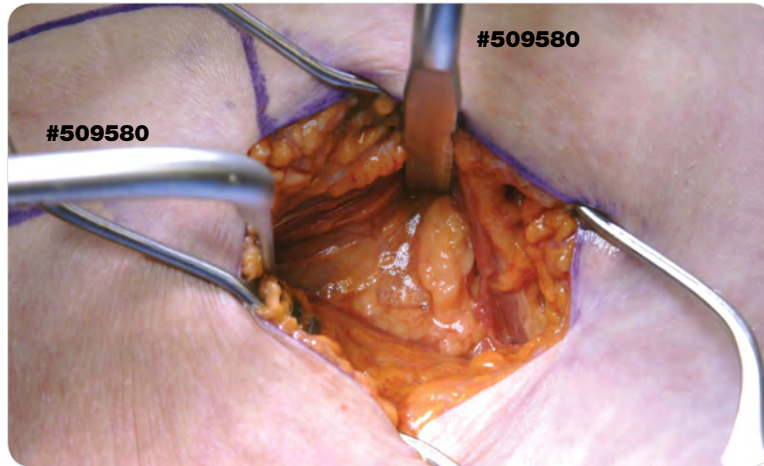


Figure 6



### Caution

Due to the proximity of the sciatic nerve it is important to be cautious when removing the pericapsular fat.



### Tip from Douglas Roger, MD:

The posterior tip of the greater trochanter should be visualized and palpated and can be used as a landmark to excise the pericapsular fat and expose the underlying tendons.

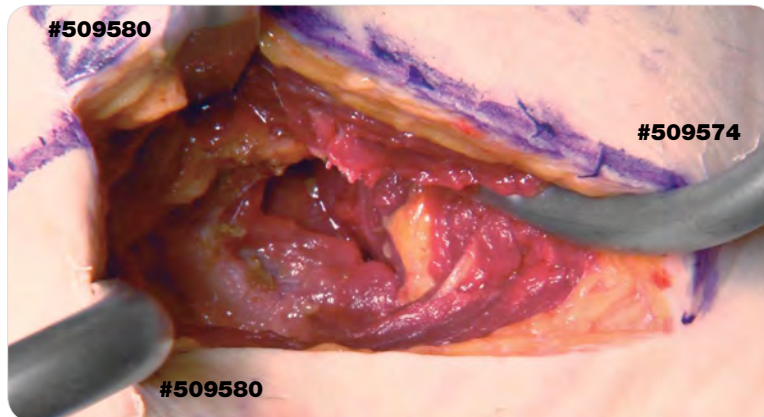


Figure 7

There is a natural plane between the gluteus medius muscle and the gluteus minimus muscle that is deep to it. The Narrow Right Angle Retractor (#509574) is placed in this plane, taking care not to injure the gluteus medius or gluteus minimus muscles (Figure 7).

The piriformis is then identified adjacent to the greater trochanter. It is round and relatively mobile. The obturator internus is identified, which is flat and relatively fixed (Figure 8). A Double Ended Retractor (#509580) is placed along the inferior border of the obturator internus tendon, retracting the inferior gemellus muscle inferiorly.

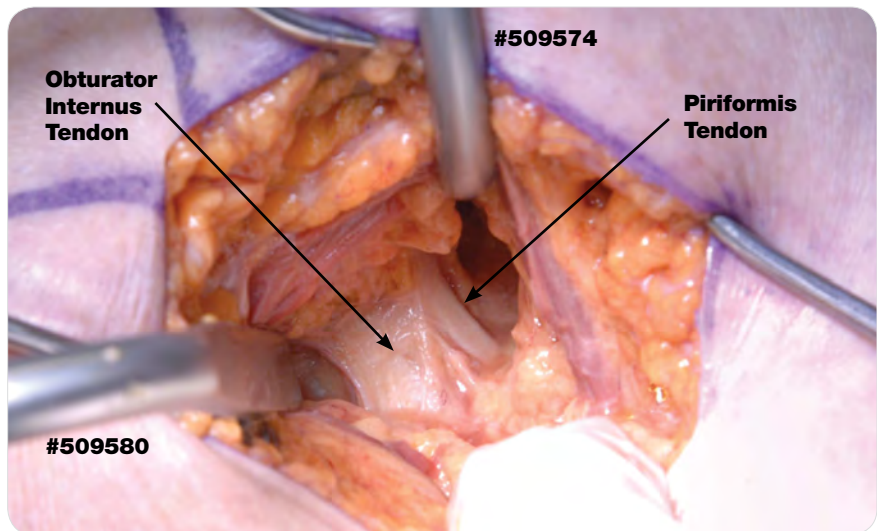


Figure 8



### Instruments

**Double Ended Retractor**  
509580



**Narrow Right Angle Retractor**  
509574





# STEP 5

## TENDON DETACHMENT AND CAPSULOTOMY

The confluence of the obturator internus tendon and the piriformis tendon is detached as close to its femoral insertion as possible (Figure 9). The tendons are then reflected posteriorly, off the hip capsule. The tendons are then sutured to the subcutaneous tissue of the posterior skin flap, and this retracts the sciatic nerve away from the field of surgical dissection (Figures 10 and 10a).

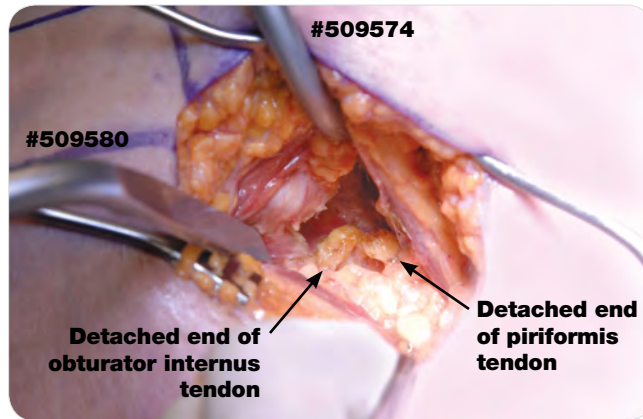


Figure 9

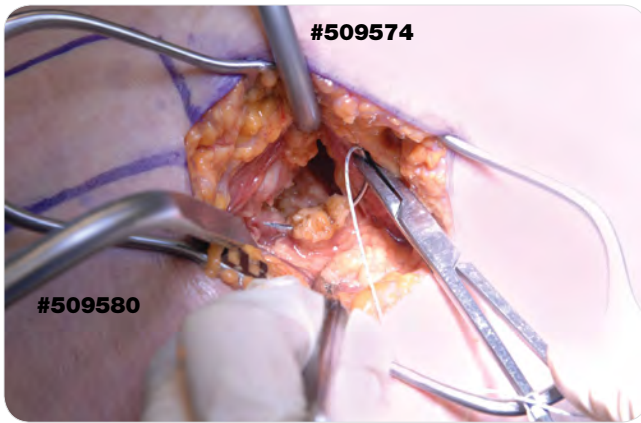


Figure 10

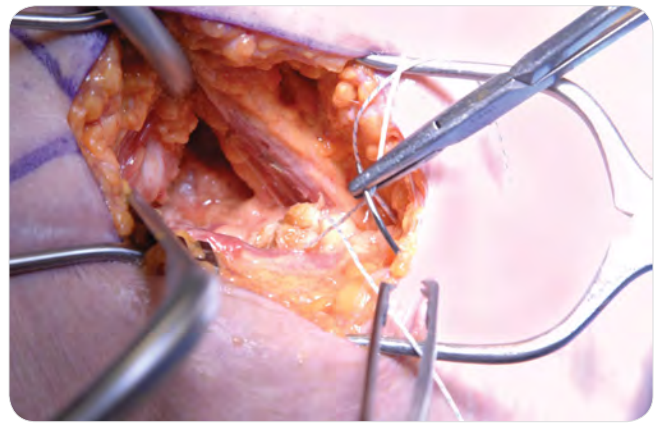


Figure 10a



### Note

**As an alternative to suturing the tendons, you have the option to tag them with a hemostat and retract posteriorly to protect the sciatic nerve.**

The capsule is then incised from anterior distal to posterior proximal, angled superiorly (Figure 11). The superior capsular flap is then elevated subperiosteally, from posterior to anterior, resecting the superior labrum. A similar elevation is done for the inferior capsular flap, resecting the posterior labrum. The capsular flaps should be elevated as much as possible prior to dislocation of the hip.

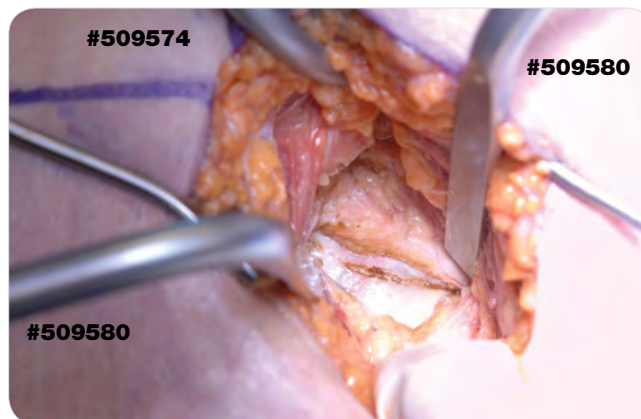


Figure 11

# STEP 6

## DISLOCATION AND FEMUR NECK RESECTION



**Tip from Anthony Hedley, MD:**

Once the femoral head and neck are exposed, the synovial tissue along the femoral neck is resected to facilitate maximum exposure.

Prior to dislocation of the hip, the Blue Handle Curved Retractor (#509576) is placed inside the capsule along the inferior femoral neck. The Curved Retractor (#509578) is placed inside the capsule along the superior femoral neck (Figure 12). The hip is then dislocated by flexion, adduction, and internal rotation.

Once the appropriate level for neck resection is determined, the femoral neck cut is made according to the surgical technique for the femoral implant. The femoral head fragment is then removed using a threaded steinmann pin or tenaculum. After the fragment is removed, it is re-measured from the center of rotation to the cut surface of the femoral neck, to confirm the length of the femoral neck resection.



**Tip from Douglas Roger, MD:**

There are many techniques for determining the appropriate level of neck resection. It may be helpful to mark the center of the femoral head at this point, and then measure from this center location down the neck (Figures 12a and 12b).

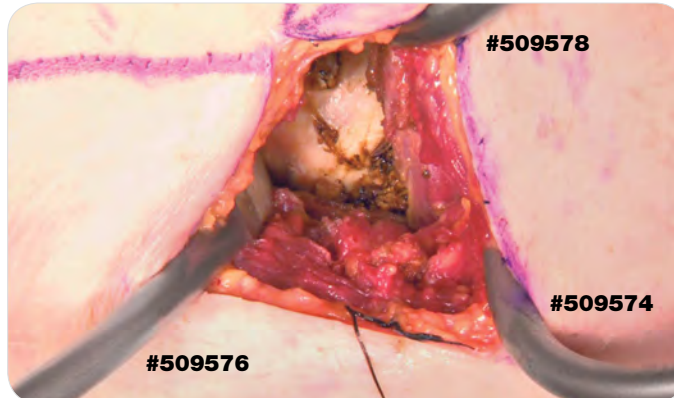


Figure 12

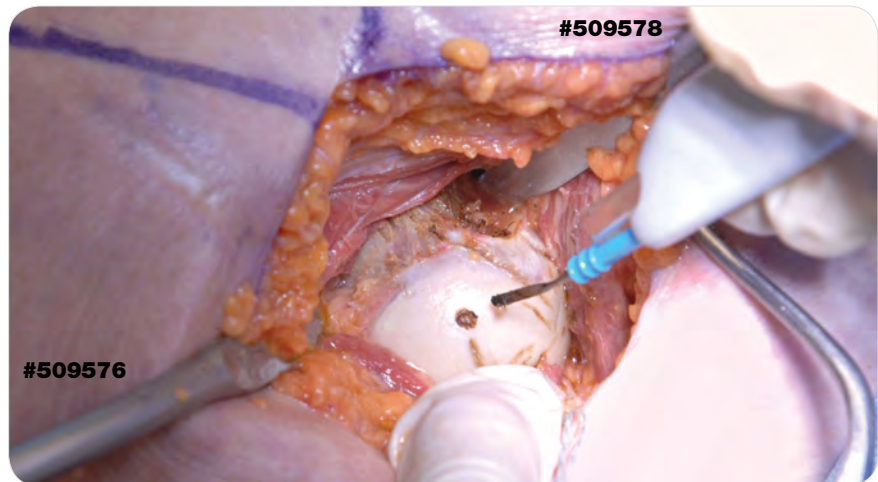


Figure 12a

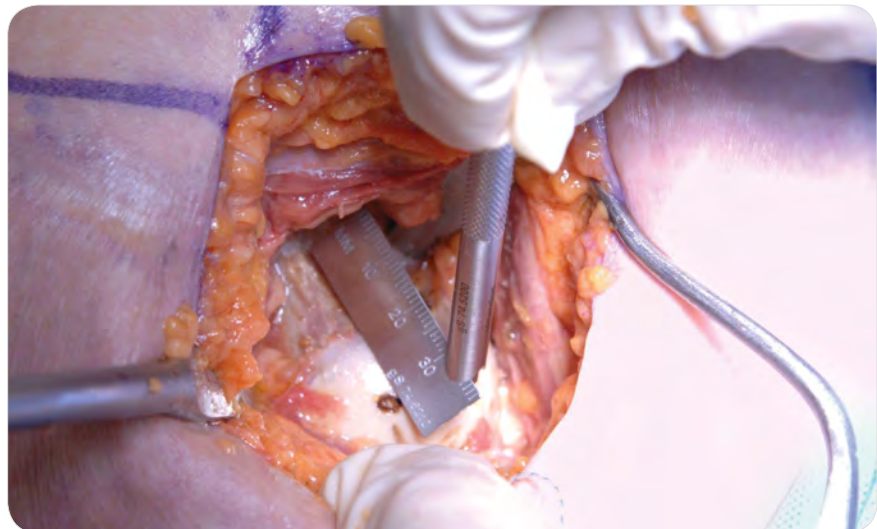

Figure 12b



### Instruments

**Blue Handle Curved Retractor**  
509576



**Curved Retractor**  
509578





# STEP 7

## EXPOSURE OF THE ACETABULUM AND RETRACTOR PLACEMENT

After osteotomy of the femoral neck, retract the proximal femur anteriorly and laterally. The Blue Handle Curved Retractor (#509576) is placed over the anterior acetabular rim.

The Narrow Right Angle Retractor (#509574) is then placed intra-capsular at the inferior margin of the acetabulum.

The hip is then abducted in order to relax the hip abductor muscles and the superior capsule. A Double Ended Retractor (#509580) is then placed deep to the superior capsule. The superior capsule is then elevated subperiosteally with a Cobb Elevator for a distance of approximately 1–2 cm from the superior margin of the acetabulum. A punch is used to create an indentation 1–2 cm above the superior rim of the acetabulum, at the 12 o'clock position.

Place the Wide Right Angle Retractor (#509575) into the indentation, deep to the superior capsule and tap into the ilium, approximately 1 cm superior to the superior rim of the acetabulum.

The hip is then placed into extension and internal rotation. After additional subperiosteal elevation of the inferior capsular flap and resection of posterior labrum, an optional fourth retractor (S-Curved Retractor #509579) may be placed on the posterior aspect of the acetabulum. See Figures 13 and 14 for suggested retractor placement.

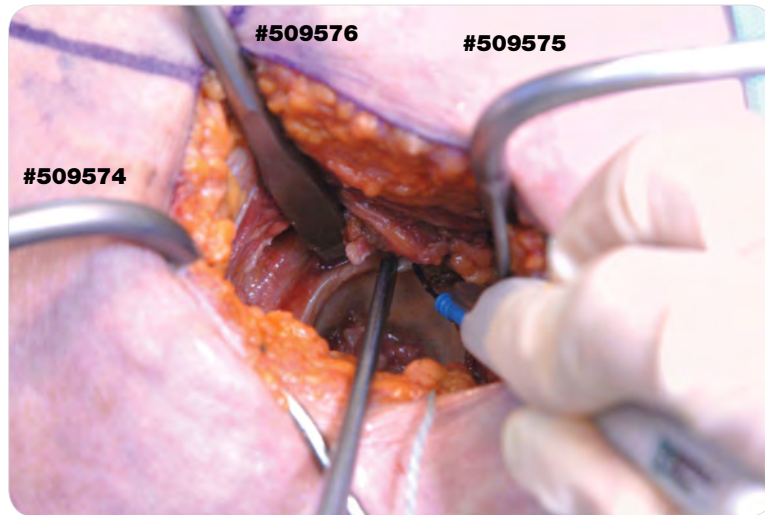


Figure 13

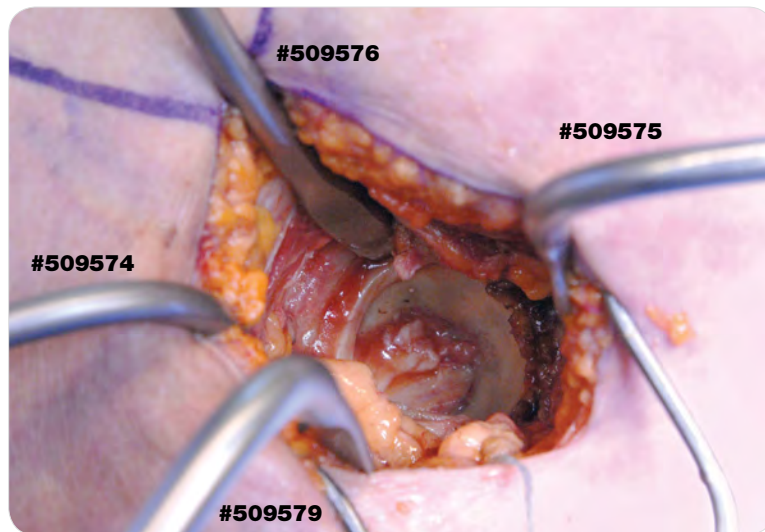


Figure 14



### Instruments

**Blue  
Handle Curved  
Retractor**  
509576

**Wide  
Right Angle  
Retractor**  
509575

**Narrow  
Right Angle  
Retractor**  
509574

**Double  
Ended  
Retractor**  
509580

**S-Curved  
Retractor**  
509579

# STEP 8

## PREPARATION OF THE ACETABULUM

Any remaining anterior labrum is resected at this time. Identify the medial wall at the base of the cotyloid notch, and the transverse acetabular ligament.

An exchange retractor technique is used for the Blue Handle Curved Retractor (#509576). A Curved Retractor (#509578) is placed at the 1 o'clock position for a right hip or at the 11 o'clock position for a left hip at the level of the anterior inferior iliac spine. After this retractor has been placed, the previously placed Blue Handle Curved Retractor (#509576) is removed. This is done in order to prevent impingement of the reamer on the 3 o'clock / 9 o'clock retractor (Figure 15).

It is recommended to initially use a straight reamer for medial acetabular reaming.

Next, the Angled Reamer (#510012) is utilized for sequential reaming to the required size, according to the surgical technique of the selected acetabular component. The handle of the Angled Reamer (#510012) is cephalad and the power source caudad during this reaming process (Figures 16 and 16a). With the reamer handle in the vertical position, the reamer abduction angle will be approximately 40 degrees to the transverse plane of the pelvis. The specific anatomy of each patient, such as pelvic tilt, may influence orientation of the reamer handle. It is recommended that the reamer be pulled away from the acetabular bone initially, so that the reamer rotates freely prior to actual contact with the bone.

Reaming sequence should be determined based on the surgical technique corresponding to the acetabular implant.

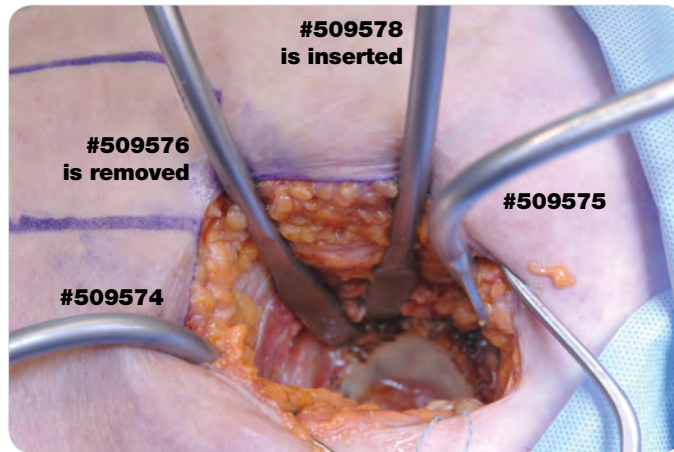


Figure 15

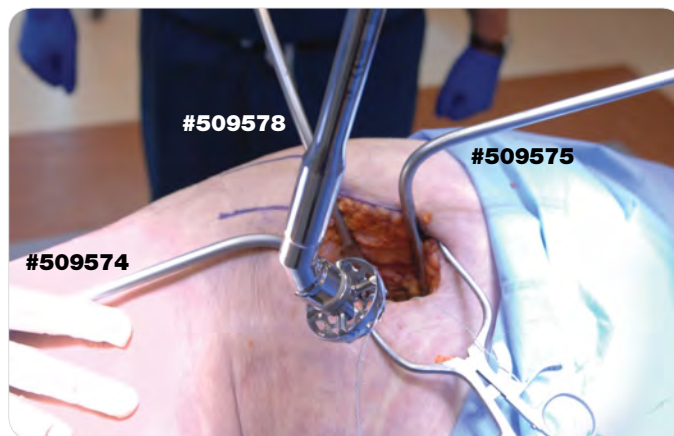


Figure 16

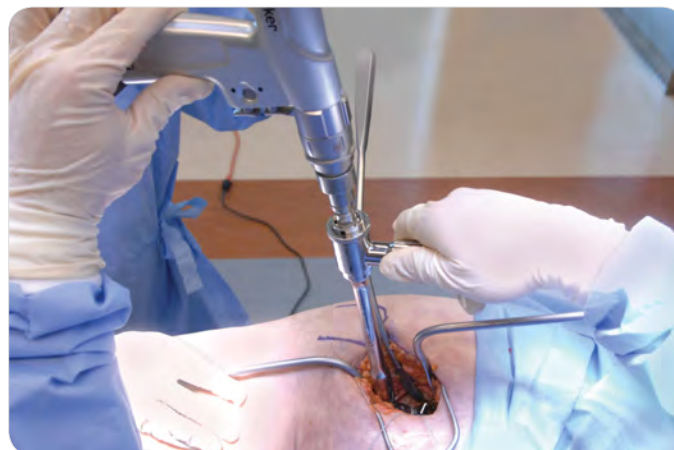

Figure 16a



### Instruments

**Angled  
Reamer  
Handle**  
510012



**Curved  
Retractor**  
509578



**Blue  
Handle Curved  
Retractor**  
509576





# STEP 9

## CUP INSERTION

Implant the cup using the Curved Cup Bolt Impactor (#1440-2010) with the Cup Impactor Bolt (#1440-2011).

Fully thread the bolt onto the cup, then place the cup in the preferred orientation before attaching the impactor.(Figure 17).

Alternatively, insert the cup using the impactor, positioning the cup on the impactor so that any screw holes are oriented as desired (Figures 18-19). Impact the cup in a manner consistent with its respective surgical technique. Avoid misdirected or excessive force.

The impactor may be detached from the bolt. By keeping the bolt attached to the cup, the cup may be assessed for orientation and quickly reattached to the impactor if needed.

To remove the bolt, partially loosen it by rotating the impactor counterclockwise. Remove by hand, with the Straight Cup Impactor (#1440-2019) or with the U-Joint Bolt Driver (#1440-2017) if access to the bolt is limited.

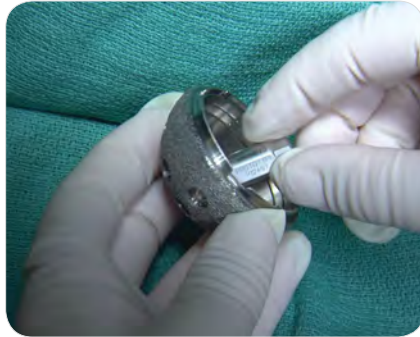

Figure 17

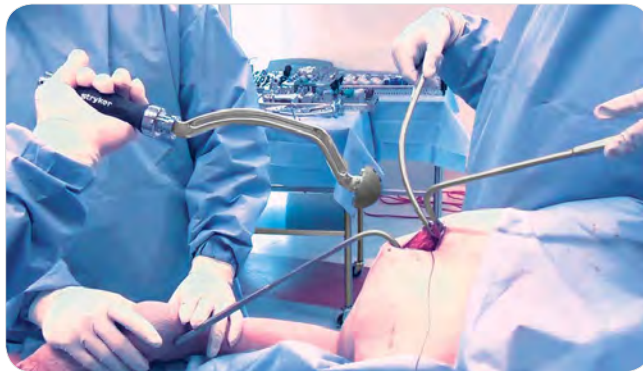


Figure 18

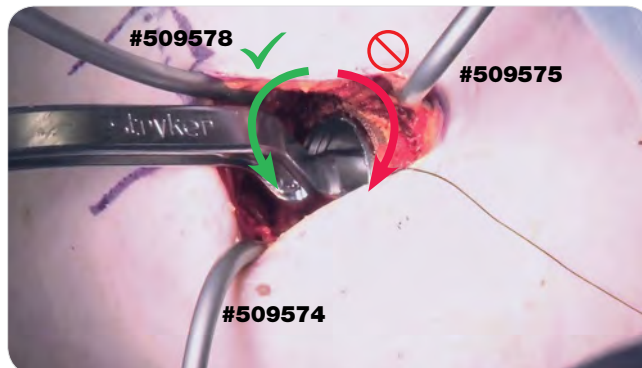


Figure 19



### Note

**Do not rotate the impactor clockwise as this will further tighten the bolt into the cup. This may make bolt removal more difficult (Figure 19)**

If the cup needs to be repositioned after trial reduction, use the Straight Cup Impactor (#1440-2019) or the U-Joint Bolt Driver (#1440-2017) to re-insert the bolt. Screw forceps will help control the U-Joint Bolt Driver (#1440-2017) during reinsertion.



### Tip from Anthony Hedley, MD:

**The cup may appear slightly horizontal from this angle. An intra-operative x-ray may be helpful at this point in determining accurate orientation of the acetabular component.**



### Instruments

**Curved Cup Bolt Impactor**  
1440-2010



**Straight Cup Bolt Impactor**  
1440-2019



**U-Joint Bolt Driver**  
1440-2017



**Cup Impactor Bolt**  
1440-2011



# STEP 9

## CUP INSERTION CONTINUED

### Lateral Decubitus Alignment Guide (Optional)



#### Note

The Lateral Decubitus Alignment Guide offers a visual reference to estimate cup inclination and anteversion.

Slide the Alignment Guide onto the Cup Impactor and rotate it around the spindle to the desired location. Align the plane of the two crossbars (line A) parallel to the mid-sagittal plane of the pelvis (line B). The mid-sagittal plane can be approximated as the long axis of the patient. This provides a visual approximation of 45° of cup inclination. Be sure to account for pelvic tilt when aligning the crossbars to the floor or OR operating table (Figures 20-21).

Align the side-specific crossbar (marked "LEFT" or "RIGHT"; line C) so that it is parallel to the long axis of the patient (line D). This alignment provides a visual approximation of 20° of cup anteversion (Figures 20-21).

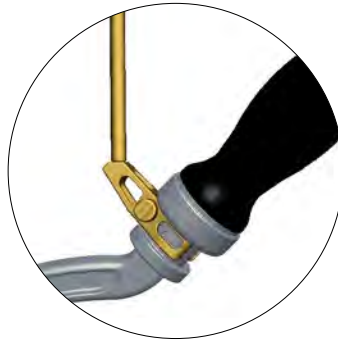

Figure 20

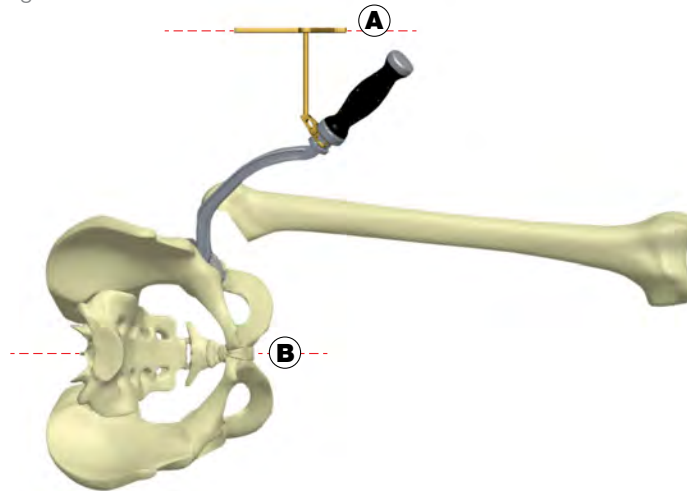


Figure 21

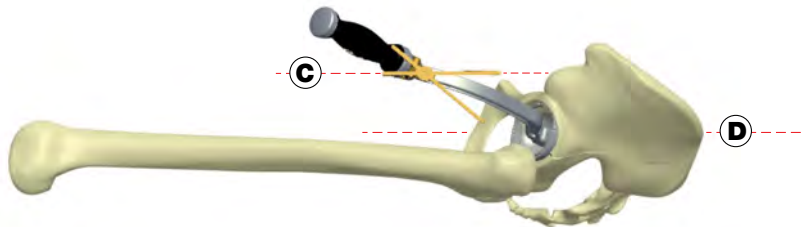


Figure 22



#### Instruments

Lateral Decubitus  
Alignment Guide  
1440-1370



# STEP 10

## FEMORAL EXPOSURE



**Tip from Douglas Roger, MD:**

For optimal femoral exposure, it may be helpful to loosen the anterior pelvic positioner to allow for slight forward rotation of the pelvis.

Transitioning from acetabular exposure to femoral exposure is done without allowing the wound to close.

The Narrow Right Angle Retractor (#509574) is removed, and replaced with a Double Ended Retractor (#509580) (Figure 23). The Curved Retractor (#509578) is then removed, which allows the proximal femur to be brought in to a more posterior and superior position in the wound. The hip is placed in to the 40-40-40 position, with 40 degrees of flexion, 40 degrees of internal rotation, and 40 degrees of adduction, and adjusted as necessary, with particular emphasis on adduction of the hip (Figure 24). If visualization of the cut surface of the neck is limited, further internally rotate the hip.

The Narrow Right Angle Retractor (#509574) will now replace the Wide Right Angle Retractor (#509575) and is placed over the anterior cortex of the proximal femur, at the junction of the base of the anterior trochanter and the anterior femoral neck (Figure 25).

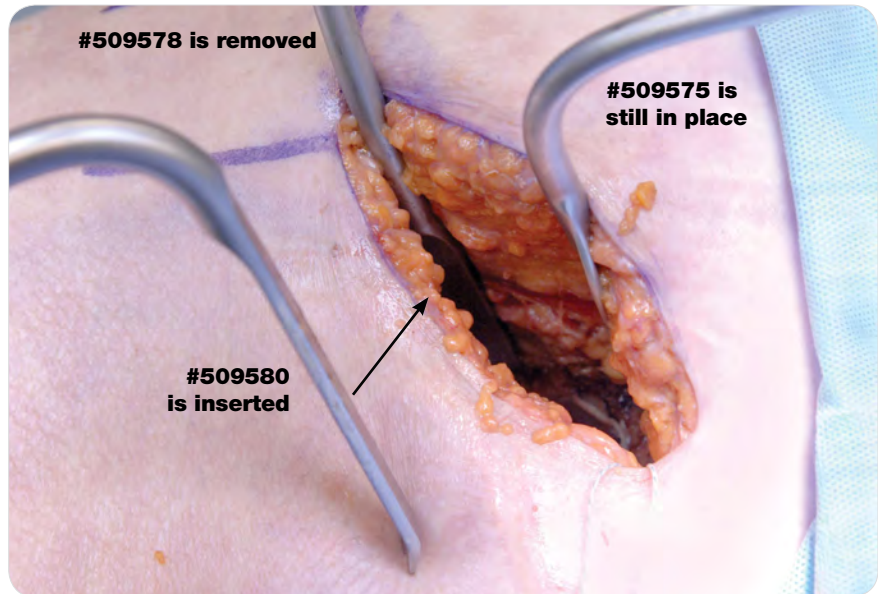


Figure 23

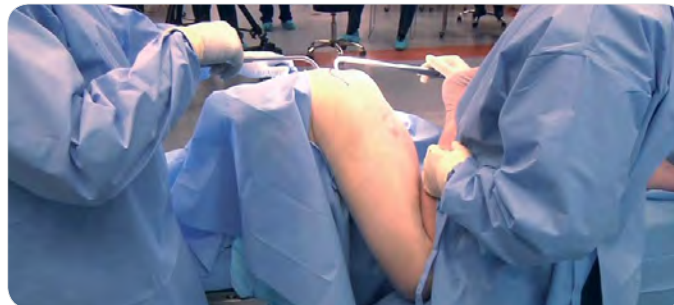

Figure 24

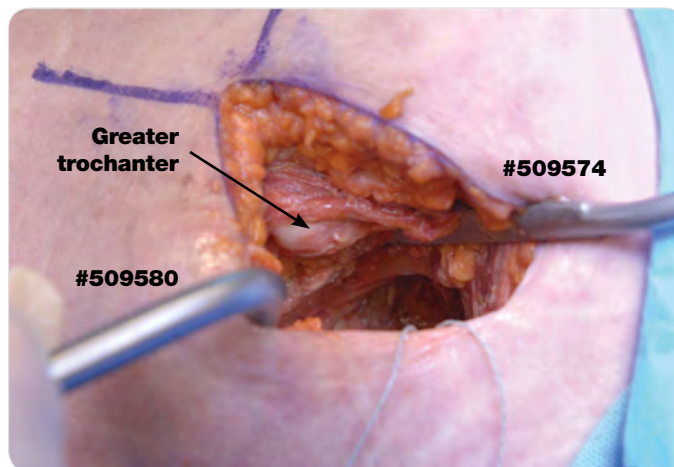


Figure 25



### Instruments

**Narrow Right Angle Retractor**  
509574



**Double Ended Retractor**  
509580



**Curved Retractor**  
509578



**Wide Right Angle Retractor**  
509575





# STEP 10

## FEMORAL EXPOSURE CONTINUED

The proximal femur should now be in the central portion of the wound. The Femoral Neck Elevator (#509577) is then placed under the anterior femoral neck. An optional Wide Right Angle Retractor (#509575) can be placed on the medial aspect of the calcar to retract the quadratus femoris and the obturator externus away from the proximal femur, replacing the Double Ended Retractor (#509580) (Figure 26).

During preparation of the femur, spatial orientation is critical for femoral anteversion, since the leg is at the 40-40-40 position compared to a position of 90 degrees of flexion, 90 degrees of internal rotation (Figure 27).

For femoral preparation and sequential broaching, please refer to the surgical technique for the implant.

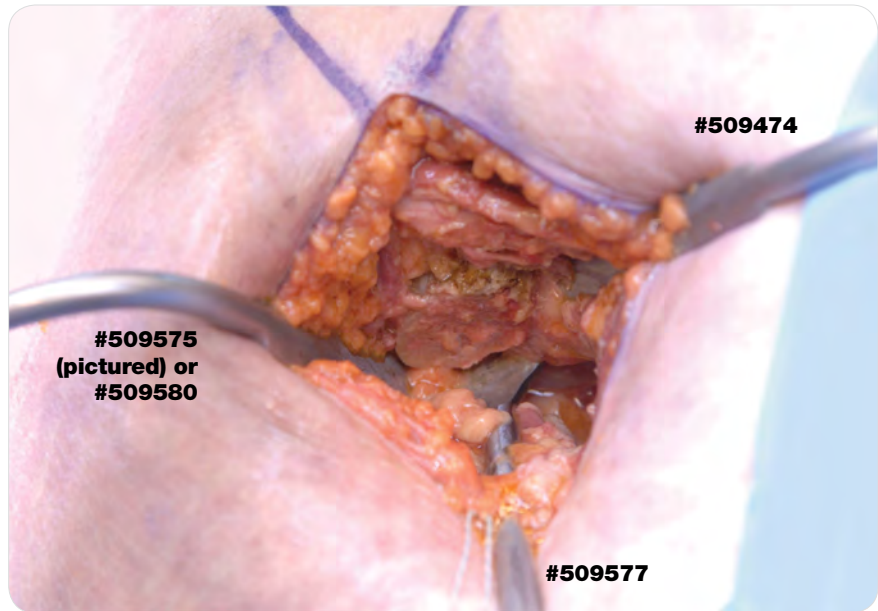


Figure 26

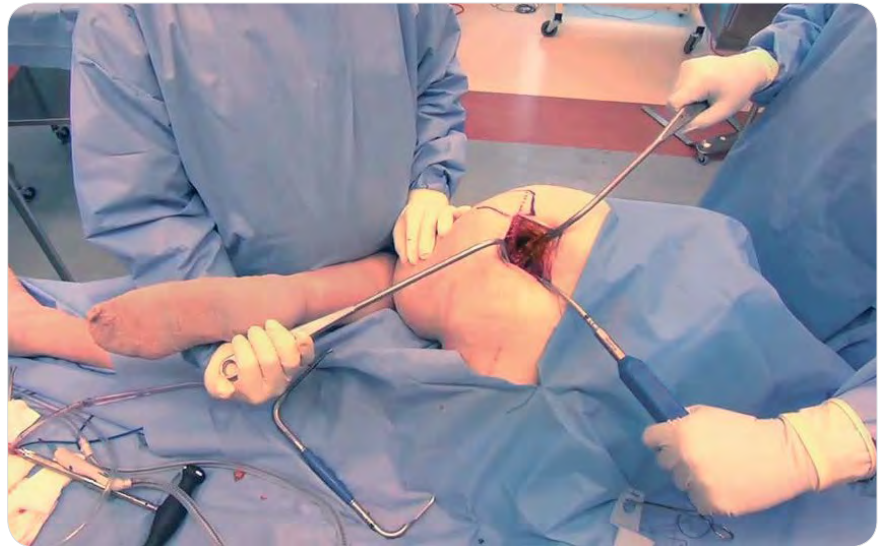


Figure 27



### Instruments

**Femoral Neck Elevator**  
509577



**Wide Right Angle Retractor**  
509575



**Double Ended Retractor**  
509580





# STEP 11

## CAPSULAR REPAIR

The hip is placed into extension and slight internal rotation. A Double Ended Retractor (#509580) is used to retract the gluteus medius superiorly. The anterior portion of the superior capsular leaflet is identified. The anterior portion of the superior and inferior leaflets are sutured. The capsule is then closed using a running suture from anterior to posterior (Figure 28).

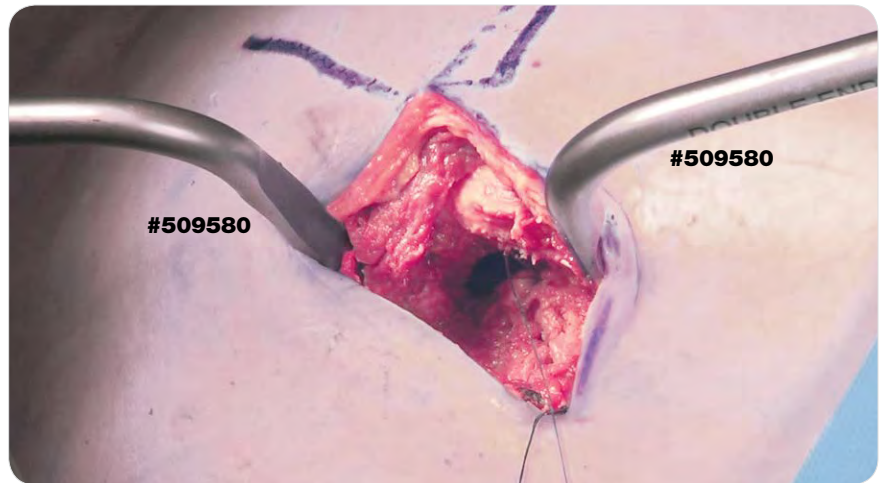


Figure 28

# STEP 12

## TENDON REPAIR

The obturator internus tendon and piriformis tendon are repaired (Figure 29). The superficial gluteus maximus fascia is closed from anterior to posterior. Tissue and skin are closed according to surgeon preference.

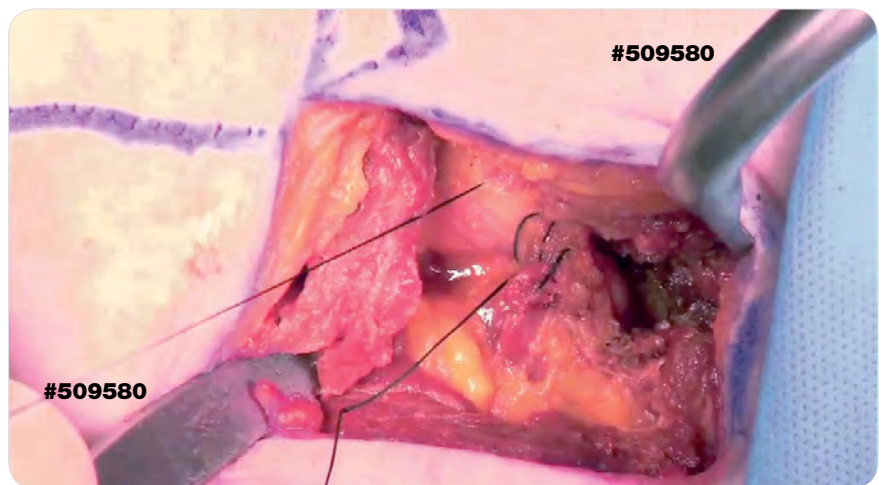


Figure 29



### Instruments

Double  
Ended  
Retractor  
509580







[www.stryker.com](http://www.stryker.com)

A surgeon must always rely on his or her own professional clinical judgment when deciding whether to use a particular product when treating a particular patient. Stryker does not dispense medical advice and recommends that surgeons be trained in the use of any particular product before using it in surgery.

The information presented is intended to demonstrate the breadth of Stryker product offerings. A surgeon must always refer to the package insert, product label and/or instructions for use before using any Stryker Product. The products depicted are CE marked according to the Medical Device Directive 93/42/EEC. Products may not be available in all markets because product availability is subject to the regulatory and/or medical practices in individual markets. Please contact your Stryker representative if you have questions about the availability of Stryker products in your area.

Stryker Corporation or its divisions or other corporate affiliated entities own, use or have applied for the following trademarks or service marks: Accolade, Anato, Secur-Fit, Stryker, Stryker Orthopaedics, Trident, Tritanium. All other trademarks are trademarks of their respective owners or holders.

DISUPR-SP-1 Rev. 2

Copyright © 2016 Stryker  
Printed in USA